



Serkan DÜNDAR <sup>1,a</sup>  
Alihan BOZOĞLAN <sup>1,b</sup>  
Tuba TALO YILDIRIM <sup>1,c</sup>  
Mehmet GÜL <sup>2,d</sup>  
Mustafa KIRTAY <sup>3,e</sup>  
Ferhan YAMAN <sup>4,f</sup>

<sup>1</sup> Fırat University,  
Faculty of Dentistry,  
Department of  
Periodontology,  
Elazığ, TURKEY

<sup>2</sup> Harran University,  
Faculty of Dentistry,  
Department of  
Periodontology,  
Şanlıurfa, TURKEY

<sup>3</sup> Free Dentist,  
Oral and Maxillofacial  
Surgery,  
Toronto, CANADA

<sup>4</sup> Free Dentist,  
Oral and Maxillofacial  
Surgery,  
Diyarbakır, TURKEY

<sup>a</sup> ORCID: 0000-0003-3944-1957

<sup>b</sup> ORCID: 0000-0003-3420-5816

<sup>c</sup> ORCID: 0000-0002-7577-5703

<sup>d</sup> ORCID: (0000-0002-5721-8778

<sup>e</sup> ORCID: 0000-0001-6598-2541

<sup>f</sup> ORCID: 0000-0002-7583-2341

Received : 04.04.2019  
Accepted : 22.07.2019

#### Correspondence Yazışma Adresi

Serkan DÜNDAR  
Fırat University,  
Faculty of Dentistry,  
Department of  
Periodontology,  
Elazığ - TURKEY

sdundar@firat.edu.tr

## Effects of Systemic Zoledronic Acid Application on Bone Implant Connection of Titanium Implants After The Osseointegration Period\*

**Objective:** This study examined the effects of systemic zoledronic acid (ZA) application on bone implant connection (BIC) of titanium implants after the 4 weeks osseointegration period.

**Materials and Methods:** Twenty one adult female Wistar albino rats were used in the study. The machined surface titanium implants were surgically integrated in the corticocancellous bone of metaphyseal part of the right femur of the rats. Next, the rats were divided randomly into 3 groups: control (n=7); only titanium implants were integrated in right femoral bones and rats received no further treatment during the 8 weeks experimental period. ZA dose 1 group (n=7); and ZA dose 2 group (n=7). A single dose systemic ZA applications were done in the treatment groups, 0.1 mg/kg and 0.2 mg/kg, respectively after the 4 week osseointegration period. After 4 weeks from the ZA application and 8 weeks of the experimental period, the rats were killed, and the implants and the surrounding bone tissues were harvested, and BIC ratios (%) were analysed according to non-decalcified histological procedures.

**Results:** Bone implant connection ratio was higher in the ZA treatment groups when compared to the controls (P<0.05), but no statistically significant differences were detected between the treatment groups (P>0.05).

**Conclusion:** These data suggest that the single dose application of ZA after the osseointegration period could improve BIC.

**Key words:** Zoledronic acid, osseointegration, bone implant connection, femoral bone

### Osseointegrasyon Döneminden Sonra Sistemik Zoledronik Asit Uygulamasının Titanyum İmplantların Kemik Temasına Etkileri

**Amaç:** Bu çalışmada osseointegrasyon döneminden sonra sistemik uygulanan zoledronik asitin titanyum implantların kemik temasına etkilerinin incelenmesi amaçlandı.

**Gereç ve Yöntem:** Bu çalışmaya 21 adet yetişkin dişi wistar albino sıçan dahil edildi. Tornalanmış yüzeyli titanyum implantlar deneklerin sağ femur kemiklerinin metafiziyel kısımlarındaki kortikokansellöz kemiğe cerrahi yöntemlerle yerleştirildi. Denekler rastgele kontrol (n=7), zoledronik asit doz-1 (n=7) ve zoledronik asit doz-2 (n=7) grubu olmak üzere 3 eşit gruba ayrıldı. Titanyum implantlar kontrol grubundaki deneklerin sağ femur kemiklerine yerleştirildi ve 8 haftalık deneysel düzenek boyunca ek herhangi bir işlem uygulanmadı. Zoledronik asit doz-1 (n=7) ve zoledronik asit doz 2 (n=7) gruplarındaki deneklerin sağ femur kemiklerine titanyum implantlar yerleştirilip 4 hafta osseointegrasyon için beklenildi ve sırasıyla 0.1 mg/kg (doz-1) ve 0.2 mg/kg (doz-2) zoledronik asit tek doz sistemik uygulandı. Zoledronik asit uygulamasını takiben deney gruplarındaki tüm sıçanlar 4 haftalık bekleme süresinden sonra-deneysel düzeneğin 8. haftası sonunda, sakrifiye edildi ve implantların kemikle temas yüzdesi dekalsifiye edilmemiş histolojik analiz yöntemine göre analiz edildi.

**Bulgular:** Kemik implant teması yüzdesi zoledronik asit uygulanan doz-1 ve doz-2 deney gruplarında kontrollere göre yüksek tespit edilirken (P<0.05) deney grupları arasında istatistiksel bir fark tespit edilmedi (P>0.05).

**Sonuç:** Bu çalışmanın sınırlı verilerine göre tek doz zoledronik asit osseointegrasyon döneminden sonra kemik implant temasını artırabilir.

**Anahtar Kelimeler:** Zoledronik asit, osseointegrasyon, kemik implant teması, femur kemiği

#### Introduction

Dental implant-supported prostheses are commonly used and scientifically accepted options for treating partial and complete toothlessness. In dental implant therapy, the systemic condition of the patient, the quality and quantity of the bone in which the implant will be placed, the geometric and surface characteristics of the implant, and the smoking habit of the patient are important factors for osseointegration (1-4).

\* This study supported by Fırat University Scientific Research Project Foundation Department with the project number DHF.17.03.

The length of time between surgical dental implant application and prosthetic loading, and the low rate of clinical success in the case of poor-quality bone tissues, and the maintaining the bone tissue quality in a long period are the most challenging problems in dental implant treatments (3-5). To overcome insufficient bone tissue quality and quantity, different dental implant treatment techniques have been used to increase osseointegration and bone tissue formation. Tissue growth factors, hormones like melatonin, and antiosteoclastic drugs-biphosphonates (BPs) have been used to improve the osseointegration of titanium implants (3, 4, 6). Biphosphonates can be used in metabolic bone tissue treatment procedures. Zoledronic acid (ZA) application enhances bone tissue mineral density and the number of marrow clonogenic fibroblast progenitors after allogenic stem cell transplantation in the short term (7-9). These results have raised questions as to the effects of chronic ZA treatment on bone implant connection (BIC) and bone tissue structure. Zoledronic acid is the most potent of the BPs compounds used in a clinical setting. In the literature, it has been demonstrated that a single dose of intraoperative ZA has positive effects on different bone tissue healing models; thus, studies have shown that ZA has a positive effect on the BIC of implants (3, 7-8). However, no study has demonstrated possible ZA effects on the BIC quality of titanium implants after the osseointegration period to the extent we reach. Thus, this experimental animal study aims to evaluate the effects of systemic ZA application on the BIC levels of implants after the osseointegration period.

## Materials and Methods

**Animals and Experimental Design:** All experimental procedures in this study were performed at the Firat University Experimental Research Center, Elazig, Turkiye. This study was ethically approved by the Firat University Animal Experiments Local Ethics Committee (2017/22). Moreover, the study procedures completely conformed to the recommendations of the World Medical Association Helsinki Declaration on the protection of animals used in laboratory investigations. In this study 21 healthy adult 280–300 g female Wistar albino rats aged 1–1.2 years in the same estrus cycle were used. All the rats were kept in plastic cages, and temperatures were recorded for areas where the animals were kept. All rats were allowed for free access to food and water, and all rats were kept in the 12/12 hour light / dark cycle.

Titanium implants (Implance Dental Implant System, AGS Medical, Istanbul, Turkiye) were surgically integrated into the right femoral bones of the rats. The rats were randomly divided into the following 3 experimental groups: (1) the control group (n=7), (2) the ZA dose 1 group (n=7), and (3) the ZA dose 2 group (n=7). In the control group, only implants were integrated surgically into the femoral bones of the rat and any other treatment were not applied during the experimental period of 8 weeks. In the ZA dose 1 group and ZA dose 2 group, the implants were

integrated surgically into the right femoral bones of the rats and after the 4-week osseointegration period, respectively single doses of 0.1 and 0.2 mg/kg of ZA were applied systemically by injection in the tail vein (7, 10). In this study, ZA was applied as a single dose of 0.1 mg/kg systematically. It has been proven that the plasma concentration of the ZA gradually declines within 28 days (3, 7). Thus, a repeat dose of ZA could be administered 28 days after the initial single dose, if required, so we waited 28 days to see possible changes in BIC (7, 14). Therefore, in the present study we thought that the administration of an intra-operative systematic single dose of 0.1 mg/kg ZA would be sufficient to detect changes in osseointegration levels. After 4 weeks of ZA applications, the rats were killed, and the titanium implants and surrounding bone tissues were removed for a non-decalcified histological analysis.

**Surgical Procedures:** All the experimental surgical applications were done under sterile conditions. General anesthesia was obtained by intramuscularly injections of ketamine hydrochloride (35 mg/kg) and xylazine (5 mg/kg). After providing the general anesthesia, the surgical area of each rat was shaved and washed with povidone iodine solution. Next, a 15-mm long incision was created on the right femoral bone, and the soft tissues and periosteum were dissected in order to reach the metaphyseal part of the femoral bones (11). Implant sockets were created using drills (point drill, 1.2-mm, 1.8-mm, and 2.2-mm diameter drills were used), with perfusion of saline, and titanium implants were inserted into the metaphyseal part of the femurs, with primary stabilization. Next, the soft tissues were repositioned and sutured with 4-0 resorbable polyglactin sutures. The rats were then intramuscularly injected with an antibiotic (40 mg/kg cephalosporin) and analgesic (0.1 mg/kg tramadol hydrochloride) to prevent infection and pain. All these procedures were performed by the same researcher.

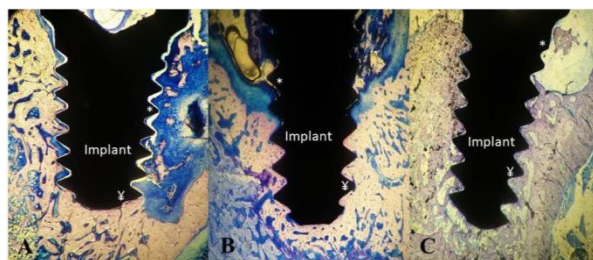
**Histological Analysis:** Any fatal and non-fatal complication such as wound infection was not detected during the 8 week experimental period. Next, the rats were sacrificed, and titanium implants, along with the surrounding bone tissues, were harvested and fixed in a 10% formalin solution for 1 week. A non-decalcified histological analysis was performed at the Faculty of Dentistry, Research Laboratory, Erciyes University, Kayseri, Turkey. For the histological analysis, the titanium implants and surrounding bone tissues were embedded in 2-hydroxyethylmetacrylate and were cut using an Exakt® microtome (Germany). After cutting the specimens in the middle, each section was ground using an Exakt® grinder to obtain 50-µm-thick sections for performing light microscopy analysis. Histological staining for BIC analysis was performed using toluidine blue. Bone-implant connection was analyzed using a light microscope and an image analyzer (Nikon, Japan) at the Department of Microbiology Laboratory, Faculty of Medicine, Firat University, Elazig, Turkiye. The BIC ratio of each specimen was calculated as the ratio of

the implant surface directly touching the bone to the total implant surface length (1, 3, 4, 7).

**Statistical Analysis:** A statistical analysis was performed using SPSS for Windows software (USA). Data for each group was shown as mean  $\pm$  standard deviation. Differences between the groups were detected using a one-way ANOVA test. Tukey's honest significant difference test was used to determine the group that caused these differences, and  $P < 0.05$  was considered statistically significant.

## Results

The results of the histomorphometric analysis of the BIC in all the groups are shown in Table 1. The BIC ratios of the rats in the ZA dose 1 and ZA dose 2 groups were higher than those of the rats in the control ( $P < 0.05$ ). However, no statistically significant differences were observed in the BIC ratios of the rats in the ZA dose 1 and ZA dose 2 groups although in ZA dose 2 group the BIC ratios higher numerically (Figure 1 A, B, C) (Table 1) ( $P > 0.05$ ).



**Figure 1.** Non-decalcified histologic images of the A: Control group, B: Zoledronic Acid Dose 1 Group, C: Zoledronic Acid Dose 2 Group (40 times magnification, Toluidin Blue. \*: Implant surfaces without bone implant connection, †: Implant surfaces with bone implant connection)

**Table 1.** Bone implant connection ratios (%) of the groups (n=7)

Groups	Bone Implant Connection Ratios (%)		P
	Mean	Std	
Control	52.49	±3.76	
ZA Dose 1	61.73	±3.48 <sup>β</sup>	<0.05*
ZA Dose 2	65.11	±6.9 <sup>β</sup>	

\*One-way ANOVA, <sup>β</sup> Tukey HSD, <sup>β</sup> Statistically significant different compared with the controls.

## Discussion

The researchers conducted various experimental animal studies (e.g., on sheep, dogs, pigs, rats, and rabbits) to evaluate the BIC of titanium implants in dental implant studies (3, 4, 6, 10-13). Rats are preferred in such studies because of their advantages, such as ease of use, appropriate bone size, and cheapness. In addition, rats had an earlier tissue reaction to the administered drug than the other experimental animals, such as rabbits, cats, and dogs, and the shorter working time makes them preferential

in experimental animal studies (10, 11). Therefore, this study was conducted with a well-established rat model for investigating the process of titanium implant osseointegration after the BIC period.

According to the results of our work, we thought that systemic ZA application could be effective for the improvement and maintaining of osseointegration after a 4-week BIC period. Data from bone cell culture studies showed that, even at very low concentrations, the use of BPs increases bone formative parameters. BPs have a direct inhibitor effect on osteoclasts and can affect bone formation due to this property. Osteoclast function may be modified by the production of an osteoclast inhibitor factor produced by osteoblasts after exposure to BPs (3, 9, 14). Bone remodeling, a lifelong process that continues after a successful BIC period, is an important factor for maintaining osseointegration. During bone remodeling process, the cells of the osteoblastic line control the activity of osteoclast cells (15). Bisphosphonates are known to increase the growth and maturation and reduce apoptosis of osteoblastic cells. All these data support the suggestion that BPs have an enhancing effect on bone tissue and promote bone tissue formation. Therefore, target cells of BPs may also include osteoblastic-derived cells. In past studies, BPs have been shown to increase the proliferation of osteoblasts and the biological synthesis of collagen and osteocalcin by bones at the cellular level (3, 7, 10).

The maxillary and mandibular bones tissue differ from long bones in several ways. The jawbone is made up of the neural crest mesoderm, mainly occurring by intramembranous ossification, mostly containing fat marrow. The jawbone is chronically exposed to the external environment and microorganisms. Another distinct feature of the jaw bones is their susceptibility to osteonecrosis associated with BP treatment (15, 16). Although BP related osteonecrosis of the jaws is a rare side effect of BP treatment, the severity of the cases and the absence of any known pathophysiology or effective treatment methods make it an important problem in dentistry. To our knowledge, there is no data on the association between single-dose administration and possible side effects of BPs after the BIC period (7, 17, 18).

The effects of ZA on the osseointegration of implants in various animal models was investigated (rabbit, rat, and dog), and in all of them, ZA has been reported to increase bone implant fusion with systemic ZA application (3, 7, 10, 11, 19). Moreover, mechanical attachment of the orthopedic implant and peri-implant bone density has been shown to be enhanced by dose-dependent systemic ZA administration. In an experimental animal study, Yıldız et al. (20) evaluated whether ZA affects bone healing around titanium implants placed in ovariectomized rabbits. The authors concluded that ZA can inhibit the negative effects of estrogen hormone deficiency on bone healing around titanium implants placed in ovariectomized rabbits. Dundar et al. (3) reported that both systemic and local ZA application increased the BIC in a female rabbit

model with 2 different implant surfaces. Additionally, Dundar et al. (3) reported that systemic ZA is a more effective method of improving BIC when compared with the local application. Dikicier et al. (10) reported similar results in their ovariectomized rat study. They reported that ZA application increased the BIC in ovariectomized rat tibias. In another study, Wise et al. (21) reported that ZA affects some of the material properties of cortical bone tissues and enables the newly formed subperiosteal bone to remain and, therefore, affects the overall quality of the bone in total hip arthroplasty. In addition, single-dose ZA application significantly reduced bone resorption in orthopedic joint replacement. After the repair of low trauma hip fracture, annual ZA infusion was associated with a reduction in the rate of new clinical fractures and improvement in survival (22).

In the present study, ZA was systematically administered as a single dose of 0.1 mg/kg and 0.2 mg/kg after the 4-week BIC period. The blood concentration of the drug has been shown to decrease gradually over a 28-day period. Thus, a repeat dose of ZA could be administered 28 days after the initial single dose, if required, so we waited 28 days after the application of the ZA (4). Therefore, in the present study, we thought the administration of a systematic single dose of 0.1 mg/kg and 0.2 mg/kg of ZA would be

effective to improve and provide long-term protection of the osseointegration of the titanium implants after the 4-week BIC period.

In conclusion, our results confirmed that systemic zoledronic acid could increase the bone implant connection after the osseointegration period. Additionally, while the results of previously conducted studies and the present study show positive effects, new studies on an optimum dosage that can possibly affect the bone implant connection after the osseointegration period and a mode of application have yet to be conducted. Additional studies are required to evaluate the effects of re-dosing on enhancing the bone implant connection of the dental implant after the osseointegration period compared with the application of a single dose.

#### Acknowledgement

The authors wish to thank Implants Dental Implant System, AGS Medical, Istanbul, Türkiye for providing the implants.

#### Conflict of Interest

The authors declare that there is no conflict of interest.

#### References

1. Dundar S, Yaman F, Bozoglan A, et al. Comparison of osseointegration of five different surfaced titanium implants. *J Craniofac Surg* 2018; 29: 1991-1995.
2. Sayardoust S, Omar O, Norderyd O, Thomsen P. Clinical, radiological, and gene expression analyses in smokers and non-smokers, Part 2: RCT on the late healing phase of osseointegration. *Clin Implant Dent Relat Res* 2017; 19: 901-915.
3. Dundar S, Yaman F, Gecor O, et al. Effects of local and systemic zoledronic acid application on titanium implant osseointegration: An experimental study conducted on two surface types. *J Craniofac Surg* 2017; 28: 935-938.
4. Dundar S, Yaman F, Saybak A, et al. Evaluation of effects of topical melatonin application on osseointegration of dental implant: An experimental study. *J Oral Implantol* 2016; 42: 386-389.
5. Dereka X, Calciolari E, Donos N, Mardas N. Osseointegration in osteoporotic-like condition: A systematic review of preclinical studies. *J Periodontol Res* 2018; 53: 933-940.
6. Muñoz F, López-Peña M, Miño N, et al. Topical application of melatonin and growth hormone accelerates bone healing around dental implants in dogs. *Clin Implant Dent Relat Res* 2012; 14: 226-235.
7. Ayan M, Dolanmaz D, Mihmanlı A, Ayan A, Kürkcü M. The effect of systemically administered zoledronic acid on the osseointegration of dental implants. *Oral Dis* 2012; 18: 802-808.
8. Dundar S, Artas G, Acikan I, et al. Comparison of the effects of local and systemic zoledronic acid application on mandibular distraction osteogenesis. *J Craniofac Surg* 2017; 28: 621-625.
9. Erdem NF, Gümüşer Z. Bifosfonat kullanımına bağlı çene kemiklerinde görülen osteonekroz vakalarının medikal ve cerrahi tedavileri sonrası uzun dönem takipleri. *Atatürk Üniv Diş Hek Fak Derg* 2019; 29: 89-97.
10. Dikicier E, Karaçaylı Ü, Dikicier S, Günaydın Y. Effect of systemic administered zoledronic acid on osseointegration of a titanium implant in ovariectomized rats. *J Craniomaxillofac Surg* 2014; 42: 1106-1111.
11. Dikicier S, Dikicier E, Karacaylı U, Erguder B. Radiodensitometric study for evaluation of bone mineral density around dental implants after zoledronic acid treatment in ovariectomized rats. *Med Oral Patol Oral Cir Bucal* 2017; 22: 377-382.
12. Lahens B, Lopez CD, Neiva RF, et al. The effect of osseodensification drilling for endosteal implants with different surface treatments: A study in sheep. *J Biomed Mater Res B Appl Biomater* 2019; 107: 615-623.
13. Coelho PG, Pippenger B, Tovar N, et al. Effect of obesity or metabolic syndrome and diabetes on osseointegration of dental implants in a miniature swine model: A pilot study. *J Oral Maxillofac Surg* 2018; 76: 1677-1687.
14. Dundar S, Ozgur C, Yaman F, et al. Guided bone regeneration with local zoledronic acid and titanium barrier: An experimental study. *Exp Ther Med* 2016; 12: 2015-2020.
15. Thiem DG, Adam M, Ganz C, Gerber T, Kämmerer PW. The implant surface and its role in affecting the dynamic processes of bone remodeling by means of distance osteogenesis: A comparative in vivo study. *Int J Oral Maxillofac Implants* 2019; 34: 133-140.

16. Otto S, Marx RE, Tröltzsch M, et al. Comments on "diagnosis and management of osteonecrosis of the jaw: A systematic review and international consensus". *J Bone Miner Res* 2015; 30: 1113-1115.
17. Ruggiero SL. Bisphosphonate-related osteonecrosis of the jaw (BRONJ): Initial discovery and subsequent development. *J Oral Maxillofac Surg* 2009; 67: 13-18.
18. Ruggiero SL, Mehrotra B, Rosenberg TJ, Engroff SL. Osteonecrosis of the jaws associated with the use of bisphosphonates: A review of 63 cases. *J Oral Maxillofac Surg* 2004; 62: 527-534.
19. Jakobsen T, Bechtold JE, Søballe K, et al. Local delivery of zoledronate from a poly (d,l-lactide)-coating increases fixation of hydroxy-coated implants. *J Orthop Res* 2017; 35: 974-979.
20. Yıldız A, Esen E, Kürkçü M, et al. Effect of zoledronic acid on osseointegration of titanium implants: An experimental study in an ovariectomized rabbit model. *J Oral Maxillofac Surg* 2010; 68: 515-523.
21. Wise LM, Waldman SD, Kasra M, et al. Effect of zoledronate on bone quality in the treatment of aseptic loosening of hip arthroplasty in the dog. *Calcif Tissue Int* 2005; 77: 367-375.
22. Lyles KW, Colon-Emeric CS, Magaziner JS, et al. Zoledronic acid and clinical fractures and mortality after hip fracture. *New Engl J Med* 2007; 357: 1799-1809.