

## Urachal Cyst: US, CT, and MRI Findings (Case Report)

Hanefi YILDIRIM  
Mustafa KOÇ  
Kürşad POYRAZ

Fırat Üniversitesi  
Tıp Fakültesi  
Radyoloji Anabilim Dalı  
Elazığ-TÜRKİYE

We present a 42 years old female patient with lower abdominal pain. Transabdominal ultrasonography (US) examination detected acute appendicitis and also incidentally showed an anechoic homogenous cystic mass with a thin wall, which located anterior part of the urine bladder. There was no connection seen between urinary bladder and adjacent structures. Computed tomography (CT) revealed a cystic mass at the dome of the urinary bladder and magnetic resonance imaging (MRI) findings were similar to sonographic and CT findings.

**Key Words:** Urachal cyst, Ultrasonography, Computed tomography, Magnetic resonance imaging

### Urakal Kist: US, BT ve MRG Bulguları (Olgu Sunumu)

42 yaşında, karın ağrısı şikayeti ile başvuran kadın olgunun, abdominal ultrasonografi (US) incelemesinde akut apendisit ile uyumlu görünümün yanı sıra, insidental olarak mesane anterior kesiminde lokalize, anekoik, homojen, ince duvarlı, kistik yapı tespit edildi. Kistin mesane ve diğer çevre yapılarla ilişkisi izlenmedi. Bilgisayarlı tomografi (BT) ve Manyetik rezonans görüntüleme (MRG), US bulgularına benzer bilgiler verdi.

**Anahtar Kelimeler:** Urakal kist, Ultrasonografi, Bilgisayarlı tomografi, Manyetik rezonans görüntüleme

### Introduction

Urachal cysts are more frequently seen in the infancy or young childhood with a palpable anterior abdominal wall mass or prominence of the umbilicus. If the lumen of urachus obliterates incompletely, a potential space for cystic development within this epithelial lined space occurs. Frequently, these cysts develop in the lower third of the urachus (1,2). Cyst usually remains small and asymptomatic. Occasionally, it can occur with a midline lower abdominal mass. There is a relationship between the symptoms and size of the cyst or infectious process in the cyst (3,4).

Lower abdominal US and especially CT scans are excellent methods of confirming the diagnosis. These cysts usually diagnosed by high resolution US. Their appearance and size can be various but they usually have a thin wall and trans-sonic central cavity. There is a possibility of communication between urinary bladder and abdominal wall. A micturating cystogram will exclude a bladder communication. Malignancy developing in an urachal remnant has been described more commonly in adults but occasionally in children. The differential diagnosis of a cyst includes a bladder diverticulum, umbilical hernia and ovarian cyst. It can be difficult to differentiate an infected cyst from acute appendicitis (4).

### Case report

A 42-year-old female patient admitted to our hospital with lower abdominal pain, nausea and emesis, which localized at midline. The medical history was unremarkable and laboratory data on admission were within normal limits except increased WBC. Physical examination detected abdominal distention, defence, and rebound.

Transabdominal US examination detected acute appendicitis and also incidentally showed a smooth edged, homogenous, anechoic cystic mass with posterior acoustic enhancement (Fig.1). Cyst showed localization between the urinary bladder and abdominal wall with 20 mm. in diameter.

Enhanced CT images (Fig.2) detected a cystic mass in front of the urinary bladder. Cyst was thin walled and showed homogenous hyperdense content. Cyst didn't show significant enhancement after intravenous contrast media administration. We couldn't determine any connection between the cyst and other structures.

MRI (Fig.3a, b) was performed in offer to secure a better evaluation of cyst and to characterize the lesion. The examination performed with axial, coronal and sagittal scans plans, using both T1W and T2W images without intravenous contrast medium administration.

Geliş Tarihi : 29.03.2007  
Kabul Tarihi : 09.05.2007

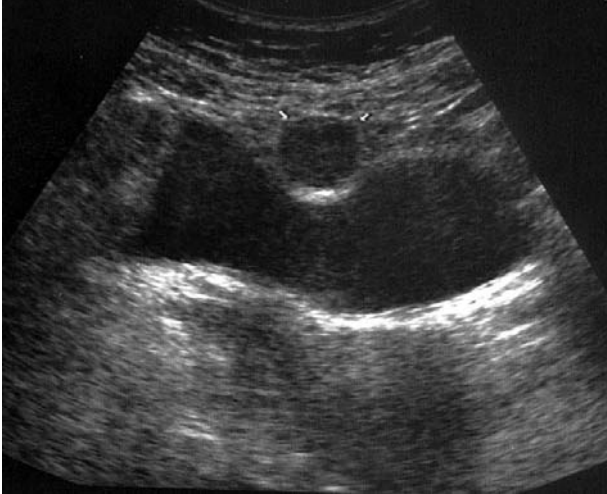### Yazışma Adresi Correspondence

Mustafa KOÇ  
Fırat Üniversitesi  
Tıp Fakültesi  
Radyoloji Anabilim Dalı  
Elazığ-TÜRKİYE

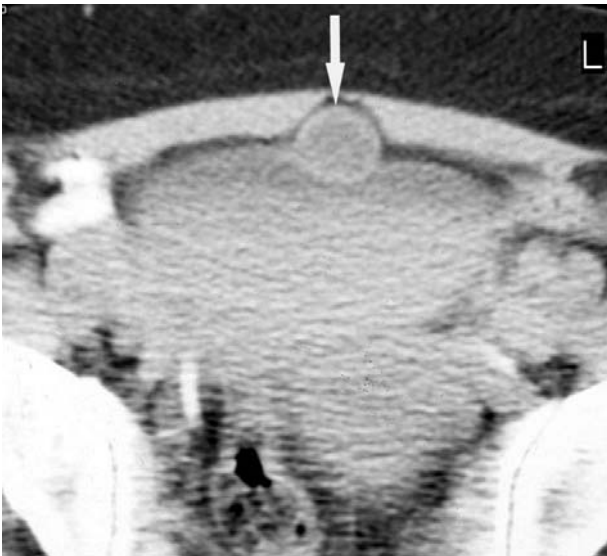
mkoca@firat.edu.tr

T1W images showed a thin walled homogenous isointense mass lesion with approximately 2 cm. in diameter, which located anterosuperior part of the urinary bladder. Contours between the urinary bladder and lesion were easily determined on sagittal and axial sections. Lesion was homogenous hyperintense on T2W images.

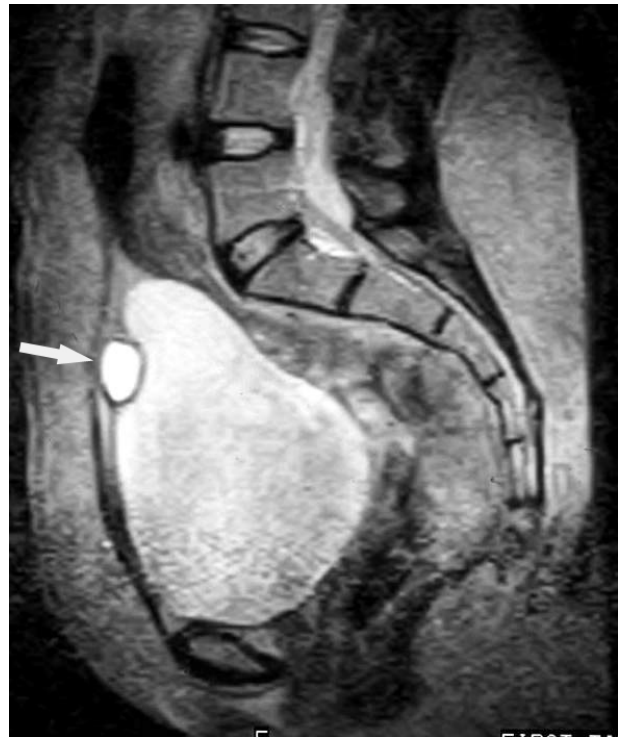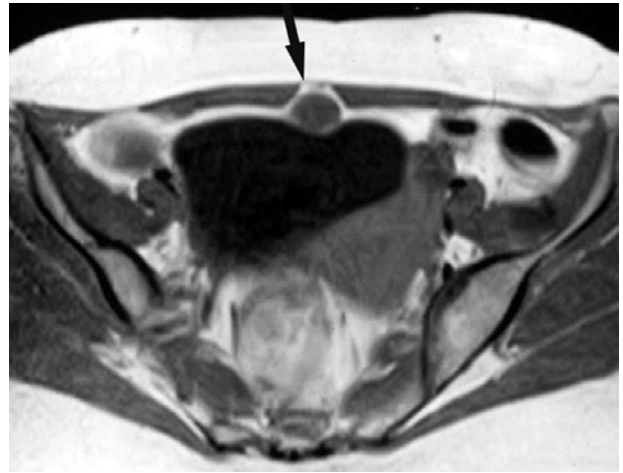
The patient had surgery after the diagnosis. Pathology report was compatible with acut appendicit and urachal cyst.



**Figure 1.** Transabdominal sonography shows an anechoic, thin walled cystic mass between the abdominal wall and urinary bladder (small arrows).



**Figure 2.** CT shows a hyperdense mass in front of the urinary bladder (arrow).



**Figure 3.** T1W axial MRI scan shows an isointense mass at the anterior of the urinary bladder (arrow) (a). Sagittal T2W MRI revealed a hyperintense mass between the abdominal wall and urinary bladder (arrow). There was not any communication between urinary bladder and abdominal wall (b).

#### Discussion

In early fetal life, the allantois connects the urogenital sinus with the umbilicus. Normally, the allantois is obliterated during development and is replaced by a fibrous cord known as the urachus or median umbilical ligament. Failure of fibrous closure of the allantois results in a variety of urachal remnants. Incomplete obliteration of the urachal lumen results in the following five anomalies: congenital patent urachus, umbilical urachal

sinus, vesicourachal diverticulum, urachal cyst, alternating sinus (1). Urachal cysts are the most common type of urachal anomaly in adults (5).

Urachal cysts may present in many ways. Some have been discovered secondary to calcification of the cyst wall, calculus formation within the cyst, acute abdominal pain secondary to hemorrhage into cyst, intraabdominal rupture leading to peritonitis or spontaneous rupture without infection. Most urachal cysts develop in the lower third of the urachus due to epithelial desquamation and degeneration. Small urachal cysts are not uncommon and are often detected incidentally, unless infection or malignant change occurs (6).

Urachal tract remnants that abnormally remain patent are often subject to infection. Furthermore, these infected remnants are frequently confused with a wide spectrum of midline intraabdominal or pelvic inflammatory disorders at clinical examination and with malignant tumors at imaging (6). Depending on the variations in the patency of the urachal lumen, the drainage of infected fluid along the urachus can determine the acquired forms of umbilical-urachal sinus, vesicourachal diverticulum, or patent urachus or alternating sinus. Rarely, spontaneous rupture of an infected cyst into the abdominal cavity leads to localized or generalized peritonitis. Complex echogenicity at US and inhomogeneous attenuation with variable contrast enhancement in and around the disease process at CT make it difficult to differentiate an infected urachal remnant from urachal carcinoma. At CT, urachal carcinoma may be solid, cystic, or a combination of the two. Low-attenuation components are seen in 60%

of cases, reflecting the mucin content (7). In our case cyst was homogenous, anechoic, not associated with infection or carcinoma.

CT or MRI is the preferred modalities for demonstration of an urachal cyst and possible secondary complications, such as tumor. Urachal diverticula may be seen at US, CT, MRI, intravenous urography or cystography. US examination and CT scan of the lower abdomen can be useful for diagnosing urachal cysts, especially for showing the relationship between the urachus and the bladder or umbilicus.

Urachal anomalies have been associated with other genitourinary conditions, such as hypospadias and crossed renal ectopia (8,9). The optimal diagnostic radiographic study depends on the presentation. A patient who presents with periumbilical drainage should have a sinogram performed, which should be diagnostic for both an urachal sinus and a patent urachus. Any child who presents with a periumbilical mass should be suspect for having an urachal cyst, and an US should be performed, which is usually diagnostic. Complete surgical excision of the urachal abnormality with a bladder cuff is recommended to avoid recurrence or development of carcinoma in unresected tissue (10).

In conclusion, urachal remnants are not exceptional and are symptomatic if complicated. US CT and MRI identify most diseases entities originating from urachal remnant. Treatment consists on total excision because there is a risk of malignant degeneration.

### Kaynaklar

1. Ueno T, Hashimoto H, Yokoyama H, Ito M, Kouda K, Kanamaru H. Urachal anomalies: ultrasonography and management. *J Pediatr Surg* 2003; 38:1203-1207.
2. Masuko T, Nakayama H, Aoki N, Kusafuka T, Takayama T. Staged approach to the urachal cyst with infected omphalitis. *Int Surg* 2006; 91:52-56.
3. Ilica AT, Menten O, Gur S, Kocaoglu M, Bilici A, Coban H. Abscess formation as a complication of a ruptured urachal cyst. *Emerg Radiol* 2007; 13:333-335.
4. Cilento BG Jr, Bauer SB, Retik AB, Peters CA, Atala A. Urachal anomalies: defining the best diagnostic modality. *Urology* 1998; 52:120-122.
5. Mesorbian HG, Zacharias A, Balcom AH, Cohen RD. Ten years of experience with isolated urachal anomalies in children. *J Urol* 1997; 158:1316-1318.
6. MacNeily AE, Koleilat N, Kiruluta HG, Homsy YL. Urachal abscesses: protean manifestations, their recognition, and management. *Urology* 1992; 40:530-535.
7. Yu JS, Kim KW, Lee HJ, et al. Urachal remnant diseases: spectrum of CT and US findings. *Radiographics* 2001; 21:451-461.
8. Rich RH, Hardy BE, Filler RM. Surgery for anomalies of the urachus. *J Pediatr Surg* 1983; 18:370-373.
9. Lane V. Congenital patent urachus associated with complete (hypospadiac) duplication of the urethra and solitary crossed renal ectopia. *J Urol* 1982; 127:990-991.
10. Bartley G, Cilento JR, Stuart B et al. Urachal Anomalies: Defining The Best Diagnostic Modality. *Pediatric Urology* 1998; 52:120-122.

