



Mehmet Gökhan ASLAN^{1, a}
Mustafa DURMUŞ^{2, b}

¹ Recep Tayyip Erdoğan
University,
Department of Eye Diseases,
Rize, TURKEY

² Çorum Private Hospital,
Eye Diseases Clinic
Çorum, TURKEY

^a ORCID: 0000-0002-3250-1606

^b ORCID: 0000-0002-9628-3433

Evaluation of Central Macular Thickness Alterations After Uneventful Phacoemulsification Surgery*

Objective: To evaluate the central macular thickness (CMT) alterations of cataract patients without any risk factors who underwent uneventful phacoemulsification surgery and investigate the incidence of Irvine Gass Syndrome (IGS) without using perioperative topical non-steroid anti-inflammatory drugs (NSAID) treatment.

Materials and Methods: Fifty eyes of 50 cataract patients formed the study group and fellow 50 eyes with no history of previous ocular surgery formed the control group. All patients underwent a routine ophthalmologic examination preoperatively, 1 day, 1 week, 1 and 3 months after surgery including visual acuity, tonometry, fundoscopy and optic coherence tomography.

Results: The mean age of the participants was 69.92±9.93 (range 41-85) years. The mean CMT of the operated eyes preoperatively, 1 day, 1 week, 1 and 3 months after surgery were 248.56±21.67, 249.08±21.36, 250.26±19.8, 254.3±24.81 and 251.36±21.3 µm, respectively. In the control eyes, those were 250.80±21.47, 251.46±21.44, 251.36±21.41, 251.3±21.51 and 251.32±20.87µm, respectively. There was a significant increase in operated eyes 1 week, 1, and 3 months after surgery compared to preoperative measurements (P<0.05). Besides, we observed IGS in one of the male patients (2%) 1 month after surgery.

Conclusion: Uneventful phacoemulsification cataract surgery increased CMT even in patients with no predisposing risk factors. Moreover, topical Nepafenac treatment may accelerate the regression of central macular edema in IGS cases.

Key words: Irvine-Gass syndrome, OCT, phacoemulsification

Komplikasyonsuz Fakoemülsifikasyon Cerrahisi Sonrası Maküla Kalınlığı Değişikliklerinin Değerlendirilmesi

Amaç: Herhangi bir risk faktörü olmayan katarakt hastalarında komplikasyonsuz fakoemülsifikasyon cerrahisi sonrası santral maküla kalınlığı (SMK) değişikliklerini değerlendirmek ve bu hastalar perioperatif topikal non-steroid anti-inflamatur ilaç (NSAİİ) tedavisi kullanmadan Irvine Gass Sendromu (IGS) insidansını araştırmak.

Gereç ve Yöntem: 50 katarakt hastasının 50 gözü çalışma grubunu ve daha önce oküler cerrahi öyküsü olmayan diğer 50 gözü kontrol grubunu oluşturdu. Tüm hastalara ameliyat öncesi ve ameliyat sonrası 1. gün, 1. hafta, 1. ve 3. ayda görme keskinliği, tonometri, funduskopi ve optik koherens tomografiyi içeren rutin oftalmolojik muayene yapıldı.

Bulgular: Katılımcıların ortalama yaşı 69.92±9.93 (aralık 41-85) yılıdır. Ameliyat öncesi, ameliyattan 1 gün, 1 hafta, 1 ve 3 ay sonra ortalama SMK değerleri sırasıyla 248.56±21.67, 249.08±21.36, 250.26±19.8, 254.3±24.81 ve 251.36±21.3 µm idi. Kontrol gözlerinde ise bu değerler sırasıyla 250.80±21.47, 251.46±21.44, 251.36±21.41, 251.3±21.51 ve 251.32±20.87µm idi. Opere gözlerde ameliyattan 1 hafta, 1 ve 3 ay sonra perioperatif ölçümlere kıyasla SMK değerlerinde anlamlı bir artış saptandı (P<0.05). Ayrıca, ameliyattan 1 ay sonra erkek hastalardan birinde (%2) IGS gözlemledik.

Sonuç: Fakoemülsifikasyon ile komplikasyonsuz katarakt cerrahisi sonrası predispozan risk faktörü olmayan hastalarda SMK artış gösterdi. Ayrıca, topikal Nepafenac tedavisi, IGS vakalarında santral maküla ödeminin gerilemesini hızlandırabilir.

Anahtar Kelimeler: Irvine-Gass syndrome, OCT, fakoemülsifikasyon

Introduction

Cataract is one of the leading reasons of preventable blindness in the world (1). With recent advances in phacoemulsification surgery, it is possible to achieve rapid vision restoration after the procedure (2). However, even after an uneventful surgery, desired visual acuity may not be obtained due to pseudophakic cystoid macular edema (PCME) (3).

The PCME, also known as Irvine-Gass Syndrome (IGS) was firstly described by Irvine in 1953 and was angiographically documented by Gass in 1966 (4, 5). Even though several studies assessed its relation with uveitis, glaucoma, diabetes, and epiretinal membrane, the exact reason remains still unclear (6–8). Its prevalence was reported between 0.1-2% percent even in patients without any risk factors (9, 10).

* TOS 2nd Live Surgery Symposium, 28 June – 1 July 2018, Istanbul -TURKEY

Received : 11.06.2020
Accepted : 05.08.2020

Correspondence Yazışma Adresi

Mehmet Gökhan ASLAN
Recep Tayyip Erdoğan
University,
Department of Eye
Diseases,
Rize - TURKEY

mehmetgokhan.aslan@erdogan.edu.tr

The IGS can be diagnosed by fundoscopy, angiography, and optic coherence tomography (OCT) (11). Among these options, OCT is the most accurate diagnostic tool with its %96 specificity and %100 sensitivity (12). It can demonstrate the alterations of retinal layers in microns, therefore, currently, it became indispensable diagnostic equipment of ophthalmology clinics as being a highly repeatable and non-invasive technic (13).

Several studies investigating macular thickness alterations after phacoemulsification surgery revealed contradictory results (14–16). Particularly, there is no consensus for the perioperative prescription of topical NSAID medications to prevent the IGS (17). Some of these studies suggested these medications as a routine regimen after surgery for all patients or only for the patients with risk factors, whereas some others found no difference between them and placebo in terms of postoperative macular thickness alterations (10, 18, 19). In this study, we evaluated the macular thickness alterations of cataract patients without any risk factors who underwent uneventful phacoemulsification surgery and investigated the incidence of IGS without using perioperative topical NSAID medications. Thus, we aimed to better understand the mechanisms related with IGS.

Materials and Methods

Study Group: This prospective, observational study included 50 cataract patients who underwent unilateral uneventful phacoemulsification surgery in a tertiary ophthalmology clinic. The operated 50 eyes formed the study group and the fellow 50 eyes with no history of previous operations formed the control group. Recep Tayyip Erdogan University Ethics Committee approval (2012/120) was granted prior to the study and all researchers agreed to follow the tenets of the Declaration of Helsinki. The patients were verbally informed about the study and written informed consent was obtained from all participants.

All patients recruited in this study underwent a routine ophthalmologic examination preoperatively, 1 day, 1 week, 1 and 3 months after surgery including spectacle-corrected distance visual acuity (CDVA) with Snellen's chart, tonometry, dilated fundoscopy and central retinal thickness measurement by OCT. Patients >40 years old, with no history of systemic diseases such as diabetes, hypertension, rheumatologic diseases and ocular diseases such as uveitis, glaucoma, retinal and vitreous disorders, and no previous ocular surgery were included in the study. Patients who had intraoperative complications such as posterior capsular rupture, Descemet's tear, and iris trauma and whose operations lasted over 15 minutes were excluded.

Surgical Procedure: The anesthesia was applied with the peribulbar injection of 2 mL lidocaine 2% (containing 1/100000 adrenaline) and 2 mL bupivacaine 0.5% mixture. After sterile draping, the conjunctiva was rinsed with povidone-iodine 5% for 3 minutes. Two side port incisions were performed with a 19G MVR blade according to the patient's eye and surgeon preferences.

Trypan blue was used to increase capsular visualization. For the patients with inadequate mydriasis, intracameral adrenaline (1/100000) was injected to dilate the pupil. The anterior chamber was filled with a dispersive viscoelastic and a 3.0 mm corneal knife was used to obtain self-sealing clear corneal incision. A 5.5-6 mm capsulorhexis was performed and hydro dissection and hydro delineation were applied until nucleus rotation was achieved. Stop and chop or quick chop techniques were used to remove the cataract with an Alcon Infinity torsional phacoemulsification machine. Cortex remnants were cleansed by bimanual irrigation/aspiration (I/A). A foldable hydrophobic intraocular lens was injected with 1.4% cohesive viscoelastic and centralized inside the capsular bag. Then, the viscoelastic was removed by bimanual I/A, and corneal incisions were hydrated after the intracameral injection of 0.1 mL Moxifloxacin hydrochloride 0.5% (Vigamox, Alcon Labs, Fort Worth, TX).

All patients received Moxifloxacin hydrochloride 0.5% (Vigamox, Alcon Labs, Fort Worth, TX) eye drops 5 times a day for a week and Prednisolone acetate 1% (Pred-forte, Allergan, USA) eye drops 8 times a day for 4 weeks in tapering doses after surgery.

OCT Measurements: The central macular thickness measurements of all subjects were performed with Cirrus HD spectral-domain OCT (Carl Zeiss Meditec Dublin, CA) by the same technician. Subjects' pupils were dilated and measurements were repeated until a clear scan was obtained with a signal strength over 6. The macular cube 5X5 mm protocol was applied for the central macular thickness measurement. The thinnest thickness of fovea centered 1mm diameter-circle which was calculated by the software was recorded for statistical analysis.

Data Analysis: Statistical analyses were performed using SPSS version 23.0 for Windows (SPSS, Inc., Chicago, IL). Sample size calculation was conducted using WSPAS: Web-Based Sample Size & Power Analysis Software. The variables were investigated with analytical methods to determine whether they were normally distributed. Descriptive statistics were presented as mean \pm SD for normally distributed variables and as median with minimum and maximum values for non-parametric variables. The chi-square test was used for categorical variables. Repeated measures ANOVA test was used to compare normally distributed values and Friedman test was used to compare non-parametric measures at different time points. Bonferroni correction was performed for multiple comparisons. Independent samples t-test was used for variables with normal distribution and the Mann Whitney-U test was used for variables without normal distribution for the comparison of differences between groups. Correlation analysis between IOP and CMT was performed with the Spearman's and Pearson correlation tests. All analyses were performed with a power of 95 % CI. The level of statistical significance was set at $P < 0.05$.

Results

The minimum sample size required to detect a significant difference using this test should be at least 47 in each group, (94 in total), considering type I error (alfa) of 0.05, power (1-beta) of 0.95, and effect size of 0.69. This study included 100 eyes of 50 patients who underwent unilateral uneventful cataract surgery. The mean age of the participants was 69.92±9.93 (41-85) years. There were 26 males (52%) and 24 females (48%). Right-eye (52%) operations were slightly higher than the left eyes (48%). The cataract types of patients are shown in Figure 1.

The median spectacle-CDVA of the operated eyes preoperatively, 1 day, 1 week, 1 and 3 months after surgery were 0.30 (0.10-0.60), 0.60 (0.10-1.00), 0.70 (0.40-1.00), 0.90 (0.40-1.00) and 1.0 (0.80-1.00), respectively. The median CDVA significantly increased in all examinations compared to initial and previous measurements (P<0.05), (Figure 2).

We observed a non-significant increase in IOP 1 day after surgery, however, the IOP significantly decreased 1 week, 1 and 3 months postoperatively compared to preoperative measurements. Even though there was a slight increase between 1st and 3rd-month measurements, that was not statistically significant (P=0.263), (Table 1, Figure 3).

The mean CMT of the operated eyes preoperatively, 1 day, 1 week, 1 and 3 months after surgery were 248.56±21.67, 249.08±21.36, 250.26±19.8, 254.3±24.81 and 251.36±21.3 µm, respectively. In the control eyes, those were 250.80±21.47, 251.46±21.44, 251.36±21.41, 251.3±21.51 and 251.32±20.87 µm, respectively. There was a significant increase in operated eyes 1 week, 1, and 3 months after surgery compared to preoperative measurements (P<0.05). On the other hand, even though there was a slight increase in the mean CMT of control eyes, that was not statistically significant in any of the measurements compared to preoperative values. We also evaluated the CMT alterations of both groups and the differences were significant at preoperative-1st and 3rd months and 1st week-1st month alteration comparisons (Table 2, Figure 4). In addition, Pearson and Spearman correlation tests between IOP and CMT alterations were non-significant at any of the time points (Table 3).

We observed IGS in one of the male patients 1 month after surgery. The operative CMT of the patient was 242 µm and it was increased to 336 µm in 1st-month measurement. The patient's CDVA was 0.3 preoperatively and that was increased to 0.5 in the postoperative 1st day and to 0.7 in the 1st week. However, it was decreased to 0.4 in the 1st-month examination. He received topical nepafenac (Nevanac, Alcon Labs, USA) 5 times a day for 2 months and his CMT decreased to 266 µm and his CDVA was 1.0 in the 3rd-month examination (Figure 5).

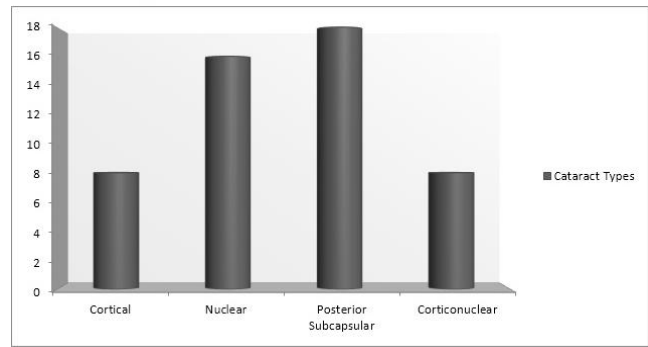


Figure 1. Cataract types of patients

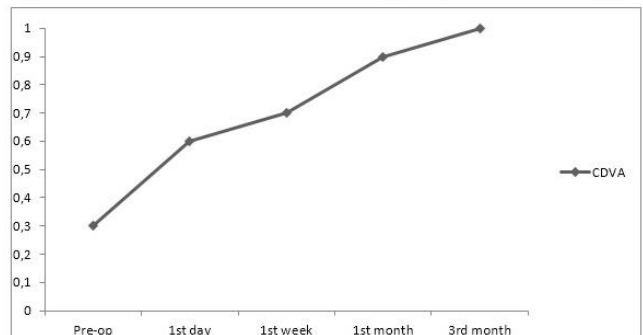
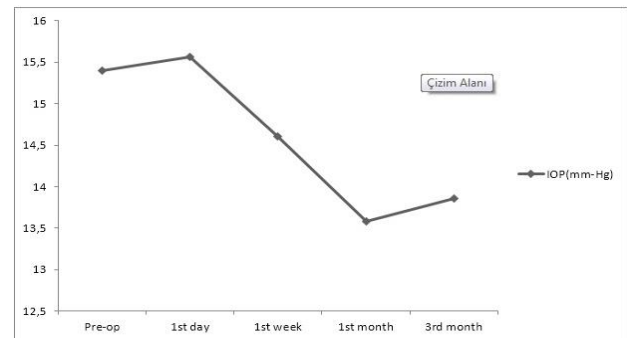
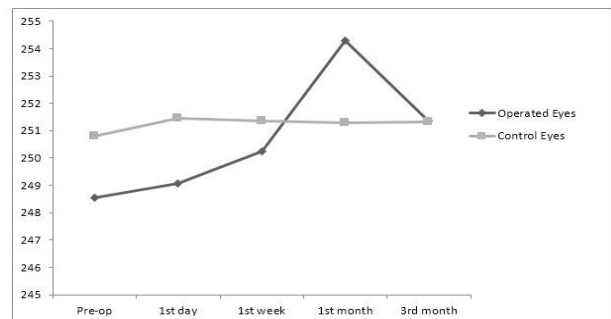


Figure 2. The median corrected distance visual acuity (CDVA) alterations after surgery



IOP: Intraocular pressure

Figure 3. The IOP alterations of operated eyes



CMT: Central macular thickness

Figure 4. The mean CMT of both groups (µm)

Table 1. The IOP measurements of the patients

IOP (mm-Hg)	N	Mean±SD	Minimum	Maximum
Pre-op	50	15.4±2.22	11	19
1st day	50	15.56±3.68	10	22
1st week	50	14.6±1.94	11	18
1st month	50	13.58±2.03	10	18
3rd month	50	13.86±2.02	10	17

IOP: Intraocular pressure, SD: Standart Deviation

Table 2. The CMT differences comparison of the two groups (µm)

	Group	N	Mean±SD	P
1st day-Preop	Operated	50	0.52±4.34	0.867
	Control	50	0.66±4.0	
1st week-Preop	Operated	50	1.7±5.65	0.251
	Control	50	0.56±4.34	
1st month-Preop	Operated	50	5.74±4.8	<0.001
	Control	50	0.5±4.4	
3rd month-Preop	Operated	50	2.8±4.61	<0.001
	Control	50	0.52±4.1	
1st week-1st day	Operated	50	1.18±5.0	0.158
	Control	50	-0.1±3.91	
1st month-1st week	Operated	50	4.04±13.9	0.011
	Control	50	-0.6±3.23	
3rd month-1st month	Operated	50	-2.94±13.54	0.187
	Control	50	0.02±3.24	

CMT: Central macular thickness, SD: Standard Deviation, Significant values are shown in bold

Table 3. Correlations between central macular thickness and intraocular pressure alterations

Time Points	Δ CMT (µm)	Δ IOP (mm-Hg)	P	r
1st Day- Preop	0.52±4.34	0.16±3.58	0.485	-0.101 ^a
1st Week- 1st Day	1.18±5.0	-0.5 (-5.0 – 4.0)	0.220	-0.177 ^b
1st Month- 1st Week	4.04±13.9	-1.0 (-4.0 – 2.0)	0.119	0.223 ^b
3rd Month – 1st Month	-2.94±13.54	0.0 (-3.0 – 4.0)	0.175	0.195 ^b

CMT: Central macular thickness, IOP: Intraocular pressure, Δ: difference ^aPearson correlation ^bSpearman correlation

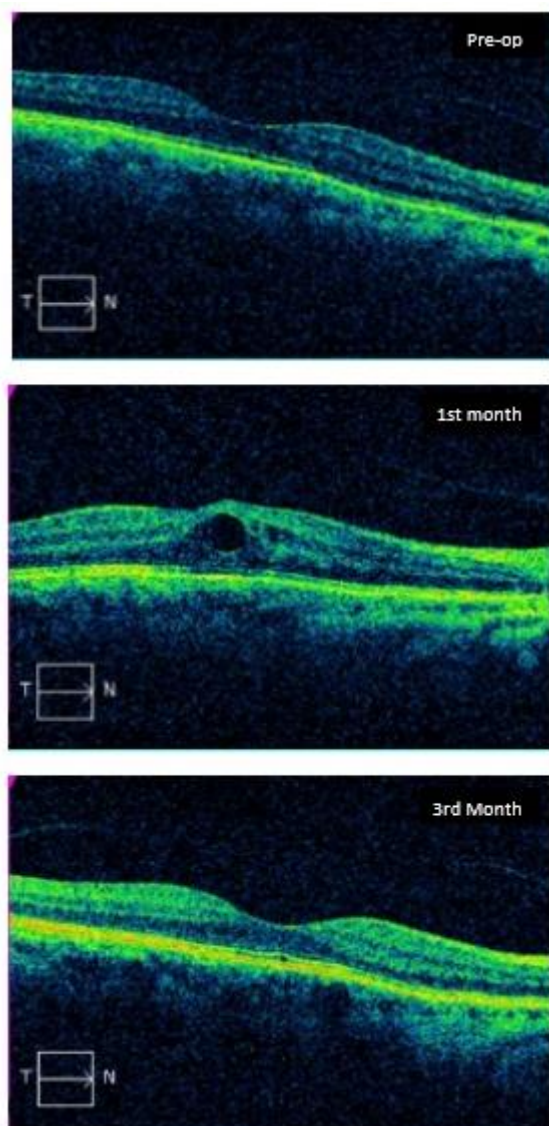


Figure 5. Preoperative, postoperative 1st and 3rd month OCT images of the Irvine-Gass Syndrome patient

Discussion

This study revealed that the mean CMT significantly increased 1 week, 1, and 3 months after uneventful phacoemulsification surgery even in patients with no risk factors for IGS. The increase reached its peak level in the postoperative 1st month and showed a declining trend in the postoperative 3rd month. We detected IGS in one of the patients (2%) of this study in postoperative 1st month and the PCME was dissolved with topical NSAID treatment in the 3rd-month examination after surgery.

The release of inflammatory cytokines such as prostaglandin and arachidonic acid leads to the breakdown of the blood-retinal barrier which causes the CME in IGS (20, 21). Besides, a positive correlation between postoperative anterior camera flare and macular thickness was previously reported which points

out the inflammatory mechanisms behind IGS (22). However, various hypotheses were proposed to explain the triggers of inflammation. Firstly, the surgical trauma, particularly iris contact, was thought to be associated with the increased inflammation (20, 23). Taipale et al reported that utilization of pupil expansion devices in cataract surgeries were related to increased risk for PCME (24). Moreover, these devices require longer surgery times which may also alleviate the inflammation. However, another study revealed that Femto-assisted cataract surgeries in which the anterior chamber manipulations are minimal, CMT alterations were also significantly reduced (25). In our study, although the surgery times of experienced surgeons were under 15 minutes and no pupil expansion device was applied, we still observed significantly increased CMT. Therefore, it is conceivable that surgical trauma may not be the only factor, even if it affects the development of the IGS. The microscope light source, which is an indispensable equipment of all surgeries, were angiographically demonstrated to cause remodeling of parafoveal vessels (26). Considering the parafoveal location of CME in the IGS, the retinal photochemical alterations induced by the microscope illumination may explain the vascular leakage.

The PCME after uneventful cataract surgery was previously demonstrated even in patients with no predisposing factors (6). Although surgical maneuvers and light exposure occur in all surgeries, only very few patients suffer IGS. In an animal model, Xu et al reported that surgical interventions induce expression of chemokine ligand 2 and increased interleukin-1 β upregulation in choroid and retina (27). Therefore, individual differences of gene expressions in retinal layers may explain the tendency to face this complication.

Several studies reported that the CMT peak occurs 4 to 6 weeks after cataract surgery (28, 29). Consistently, we also detected the highest CMT values in the postoperative 1st-month measurements. However, despite the increase in CMT after surgery, CDVA levels were also significantly increased over time. The mean CMT elevation is usually subclinical and does not affect visual acuity (30). It was reported that the increase in CMT after cataract surgery reaches preoperative values spontaneously in an average of 2 to 6 months (9, 28). In our study, the CMT values tended to decrease in the 3rd month after surgery, however that was still significantly higher compared to preoperative values. Besides, we observed that the CMT values were comparable in the 1st week and 3rd month after surgery. The cataract formation blocks 18-40% of the light reaching the retina and that may cause different OCT measurements due to its light scattering effect (30, 31). Hence, IOL and the new optic media after surgery may also alter the measurements.

The IOP was usually decreased after cataract surgery (32). In our study, we also observed significant decreases in IOP in the 1st week and 1st month. The retinal vasculature alterations caused by the decreased IOP may also lead to a parafoveal leak (33, 34).

However, Zhou et al did not find a correlation between the IOP and CMT (26). Similarly we also did not detect significant correlation between these two parameters in any of the examinations. Therefore, further studies are needed to explain the relationship between IOP change and CME development.

The prevalence of IGS after phacoemulsification surgery was reported between 0.1-2.3% in various studies (21, 35, 36). Although there was no risk factor, a 66-year-old male patient (2%) in this study suffered IGS in the 1st month after uneventful phacoemulsification surgery. This rate is consistent with the current literature. The PCME disappeared by topical NSAID treatment and the CMT was decreased and the CDVA was improved in the 3rd-month examination. Considering the role of inflammation in the development of IGS, topical corticosteroid eye drops alone may sometimes fail to control the postoperative inflammation. Zaczek et al. observed lower CMT values in patients receiving topical NSAID treatment after phacoemulsification surgery (37). Similarly, Tzelikis et al. reported that topical NSAIDs significantly reduced CMT but did not make a significant impact on CDVA (38). Although postoperative topical NSAID treatment was recommended in patients with known risk factors such as uveitis, VMT, diabetes, or ERM, it is controversial to recommend these medications in all cases as a routine postoperative regimen due to their ocular surface side effects (39). Besides, it was reported that postoperative CMT increase may spontaneously regress in 80-95% of cases within 3-12 months (6, 40). Even though there are plenty of topical NSAID options, topical Nepafenac was shown to be safe and effective in several studies to manage the post-phacoemulsification inflammation (24, 38).

Nevertheless, as in our case, topical Nepafenac treatment may accelerate the regression of CME in IGS cases.

This study had several limitations. Firstly, the CMT might have been detected higher or the IGS lower since the patients were followed for only 3 months and the normalization of CME may proceed up to 12 months. Secondly, none of the patients in our study routinely received topical NSAID medications, so that, it was not possible to fully evaluate the effect of this treatment on CMT. Although we obtained favorable outcomes with topical nepafenac treatment in the IGS patient, it is recommended to evaluate the efficacy of different molecules in IGS with randomized controlled studies. Finally, due to the small sample size, it may not be suitable to generalize our results. Further studies in different postoperative treatment regimens in larger groups may provide a better understanding of the mechanisms behind IGS.

In conclusion, we observed that the CMT significantly increased in the 1st week, 1st month, and 3rd month after surgery compared to the preoperative values in patients with no risk factors who underwent uneventful phacoemulsification surgery. The difference was significant compared to the fellow eye particularly in the 1st month which revealed the highest mean postoperative CMT. Besides, we observed that IGS, which occurred in a patient who did not receive postoperative topical NSAID treatment, disappeared in 2 months with topical nepafenac medication. However, more comprehensive studies are needed to recommend a routine postoperative topical NSAID regimen after phacoemulsification surgery.

References

1. Flaxman SR, Bourne RRA, Resnikoff S, et al. Global causes of blindness and distance vision impairment 1990–2020: A systematic review and meta-analysis. *Lancet Glob Heal* 2017; 5: e1221-1234.
2. Ilveskoski L, Taipale C, Holmström EJ, et al. Macular edema after cataract surgery in eyes with and without pseudoexfoliation syndrome. *Eur J Ophthalmol* 2019; 29: 504-509.
3. Nelson ML, Martidis A. Managing cystoid macular edema after cataract surgery. *Curr Opin Ophthalmol* 2003; 14: 39-43.
4. Irvine SR. A Newly defined vitreous syndrome following cataract surgery. *Am J Ophthalmol* 1953; 36: 599-619.
5. Gass JDM, Norton EWD. Cystoid macular edema and papilledema following cataract extraction: A fluorescein fundoscopic and angiographic study. *Arch Ophthalmol* 1966; 76: 646-661.
6. Chu CJ, Johnston RL, Buscombe C, et al. Risk factors and incidence of macular edema after cataract surgery: a database study of 81984 eyes. *Ophthalmology* 2016; 123: 316-323.
7. Anastasilakis K, Mourgela A, Symeonidis C, et al. Macular edema after uncomplicated cataract surgery: A role for phacoemulsification energy and vitreoretinal interface status? *Eur J Ophthalmol* 2014; 25: 192-197.
8. Schaub F, Adler W, Enders P, et al. Preexisting epiretinal membrane is associated with pseudophakic cystoid macular edema. *Graefes Arch Clin Exp Ophthalmol* 2018; 256: 909-917.
9. Lobo CL, Faria PM, Soares MA, et al. Macular alterations after small-incision cataract surgery. *J Cataract Refract Surg* 2004; 30: 752-760.
10. Wittppenn JR, Silverstein S, Heier J, et al. A randomized, masked comparison of topical ketorolac 0.4% plus steroid vs steroid alone in low-risk cataract surgery patients. *Am J Ophthalmol* 2008; 146.
11. Yoon DH, Kang DJ, Kim MJ, et al. New observation of microcystic macular edema as a mild form of cystoid macular lesions after standard phacoemulsification. *Med (United States)* 2018; 97: 1-5.
12. Biro Z, Balla Z. Foveal and perifoveal retinal thickness measured by OCT in diabetic patients after phacoemulsification cataract surgery. *Oftalmologia* 2009; 53: 54-60.
13. Guliani BP, Agarwal I, Naik MP. Effect of uncomplicated cataract surgery on central macular thickness in diabetic and non-diabetic subjects. *J Ophthalmic Vis Res* 2019; 14: 442-447.

14. Ching HY, Wong AC, Wong CC, et al. Cystoid macular oedema and changes in retinal thickness after phacoemulsification with optical coherence tomography. *Eye* 2006; 20: 297-303.
15. Ghosh S, Roy I, Biswas PN, et al. Prospective randomized comparative study of macular thickness following phacoemulsification and manual small incision cataract surgery. *Acta Ophthalmol* 2010; 88.
16. Gharbiya M, Cruciani F, Cuzzo G, et al. Macular thickness changes evaluated with spectral domain optical coherence tomography after uncomplicated phacoemulsification. *Eye* 2013; 27: 605-611.
17. Juthani VV, Clearfield E, Chuck RS. Non-steroidal anti-inflammatory drugs versus corticosteroids for controlling inflammation after uncomplicated cataract surgery. *Cochrane Database Syst Rev* 2017; 7: CD010516.
18. Stock RA, Galvan DK, Godoy R, et al. Comparison of macular thickness by optical coherence tomography measurements after uneventful phacoemulsification using ketorolac tromethamine, nepafenac, vs a control group, preoperatively and postoperatively. *Clin Ophthalmol* 2018; 12: 607-611.
19. Rossetti L, Chaudhuri J, Dickersin K. Medical prophylaxis and treatment of cystoid macular edema after cataract surgery: The results of a meta-analysis. *Ophthalmology* 1998; 105: 397-405.
20. Ursell PG, Spalton DJ, Whitcup SM, et al. Cystoid macular edema after phacoemulsification: Relationship to blood- aqueous barrier damage and visual acuity. *J Cataract Refract Surg* 1999; 25: 1492-1497.
21. Flach AJ. The incidence, pathogenesis and treatment of cystoid macular edema following cataract surgery. *TransAm Ophthalmol Soc* 1998;96:557-634.
22. Shah SM, Spalton DJ. Changes in anterior chamber flare and cells following cataract surgery. *Br J Ophthalmol* 1994; 78: 91-94.
23. Ikegami Y, Takahashi M, Amino K. Evaluation of choroidal thickness, macular thickness, and aqueous flare after cataract surgery in patients with and without diabetes: A prospective randomized study. *BMC Ophthalmol* 2020; 20: 1-7.
24. Taipale C, Holmström EJ, Ilveskoski L, et al. Incidence of pseudophakic cystoid macular edema in eyes with and without pupil expansion device. *Acta Ophthalmol* 2019; 97: 688-694.
25. Nagy ZZ, Ecsedy M, Kovács I, et al. Macular morphology assessed by optical coherence tomography image segmentation after femtosecond laser-assisted and standard cataract surgery. *J Cataract Refract Surg* 2012; 38: 941-946.
26. Zhou Y, Zhou M, Wang Y, et al. Short-Term Changes in Retinal Vasculature and Layer Thickness after Phacoemulsification Surgery. *Curr Eye Res* 2020; 45: 31-37.
27. Xu H, Chen M, Forrester JV, et al. Cataract surgery induces retinal pro-inflammatory gene expression and protein secretion. *Investig Ophthalmol Vis Sci* 2011; 52: 249-255.
28. Vukicevic M, Gin T, Al-Qureshi S. Prevalence of optical coherence tomography-diagnosed postoperative cystoid macular oedema in patients following uncomplicated phaco-emulsification cataract surgery. *Clin Exp Ophthalmol* 2012; 40: 282-287.
29. Jagow B, Ohrloff C, Kohnen T. Macular thickness after uneventful cataract surgery determined by optical coherence tomography. *Graefe's Arch Clin Exp Ophthalmol* 2007; 245: 1765-1771.
30. Perente I, Utine CA, Ozturker C, et al. Evaluation of macular changes after uncomplicated phacoemulsification surgery by optical coherence tomography. *Curr Eye Res* 2007; 32: 241-247.
31. Artigas JM, Felipe A, Navea A, et al. Spectral transmission of the human crystalline lens in adult and elderly persons: Color and total transmission of visible light. *Investig Ophthalmol Vis Sci* 2012; 53: 4076-4084.
32. Leal I, Chu CJ, Yang YY, et al. Intraocular Pressure Reduction After Real-world Cataract Surgery. *J Glaucoma* 2020; 29: 689-693.
33. Grunwald JE, Sinclair SH, Riva CE. Autoregulation of the retinal circulation in response to decrease of intraocular pressure below normal. *Invest Ophthalmol Vis Sci* 1982; 23: 124-127.
34. Zhao Z, Wen W, Jiang C, et al. Changes in macular vasculature after uncomplicated phacoemulsification surgery: Optical coherence tomography angiography study. *J Cataract Refract Surg* 2018; 44: 453-458.
35. Daien V, Korobelnik JF, Delcourt C, et al. French Medical-Administrative Database for Epidemiology and Safety in Ophthalmology (EPISAFE): The EPISAFE Collaboration Program in Cataract Surgery. *Ophthalmic Res* 2017; 58: 67-73.
36. Bellocq D, Mathis T, Voirin N, et al. Incidence of Irvine gass syndrome after phacoemulsification with spectral-domain optical coherence tomography. *Ocul Immunol Inflamm* 2019; 27: 1224-1231.
37. Zaczek A, Artzen D, Laurell CG, et al. Nepafenac 0.1% plus dexamethasone 0.1% versus dexamethasone alone: Effect on macular swelling after cataract surgery. *J Cataract Refract Surg* 2014; 40: 1498-1505.
38. Tzelikis PF, Morato CS, Neves NT, et al. Intraindividual comparison of nepafenac 0.3% for the prevention of macular edema after phacoemulsification. *J Cataract Refract Surg* 2018; 44: 440-446.
39. Guidera AC, Luchs JI, Udell IJ. Keratitis, ulceration, and perforation associated with topical nonsteroidal anti-inflammatory drugs. *Ophthalmology* 2001; 108: 936-944.
40. Packer M, Lowe J, Fine H. Incidence of acute postoperative cystoid macular edema in clinical practice. *J Cataract Refract Surg* 2012; 38: 2108-2111.